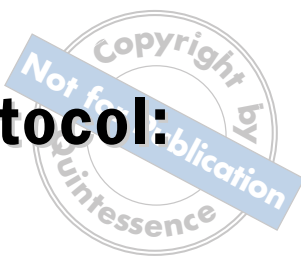

# An Unusual Serial Extraction Protocol: A Diagnostic Challenge



Nabeel Talic, BDS, MS<sup>1</sup>/Cyril Sadowsky, BDS, MS<sup>2</sup>

**Aim:** *The decision to extract four premolars in a malocclusion exhibiting crowding where the patient has a relatively flat profile can be a diagnostic challenge. When a serial extraction protocol is used, progress records are important and may lead to a change in the treatment plan.* **Methods:** *The orthodontic treatment of a serial extraction case with a subtle Class II, Division 1 malocclusion is presented.* **Conclusion:** *As time progressed, the decision was made to extract two maxillary premolars but only one mandibular premolar. The post-treatment outcome reflects a viable treatment strategy for Class II subdivision malocclusions.* World J Orthod 2001;2:258–265.

This article describes the treatment of a patient with significant crowding of both dental arches and a retrusive profile. The treatment plan was to follow a serial extraction protocol, culminating in the extraction of four first premolars. However, as time progressed, only three premolars were extracted as a consequence of a subtle but clinically significant mandibular arch asymmetry.

## HISTORY AND CLINICAL EXAMINATION

A Caucasian female, 10 years 8 months of age, had a chief complaint of crooked front teeth. Her past medical history was noncontributory. She had previous routine dental care and good oral hygiene. Her attitude toward orthodontic treatment was excellent. She was in the middle mixed dentition stage with delayed dental eruption. The attached gingiva was adequate and there was no abnormality or discoloration of the teeth. Her pediatric dentist had extracted the four deciduous canines 14 months earlier (Fig 1a), when the patient was 9 years 4

months of age, to allow for improved eruption of the permanent lateral incisor teeth (Figs 1b to 1f).

### Facial soft tissue

The soft tissue profile (Figs 2a to 2c) was slightly convex but orthognathic. The nasolabial angle was obtuse. The lips were together at rest and unstrained on closure; while in good balance, they were not harmonious and were somewhat retrusive in relation to the rest of the face. The maxillary midline was centered to the face, and the maxillary gingival display was normal upon smiling.

### Occlusal analysis

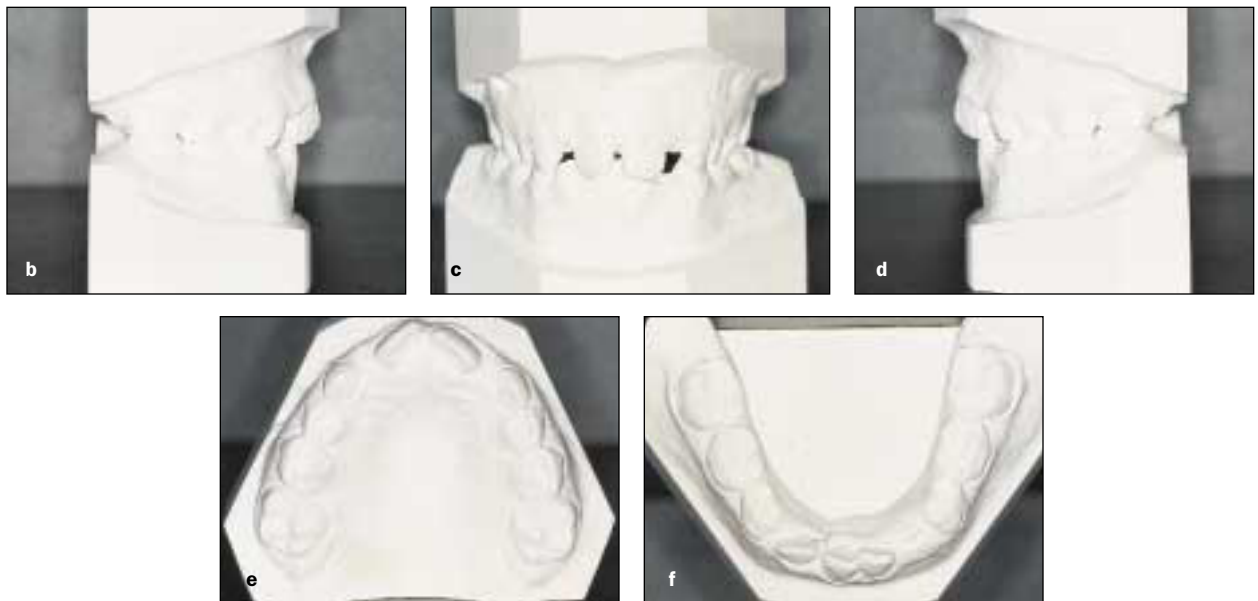
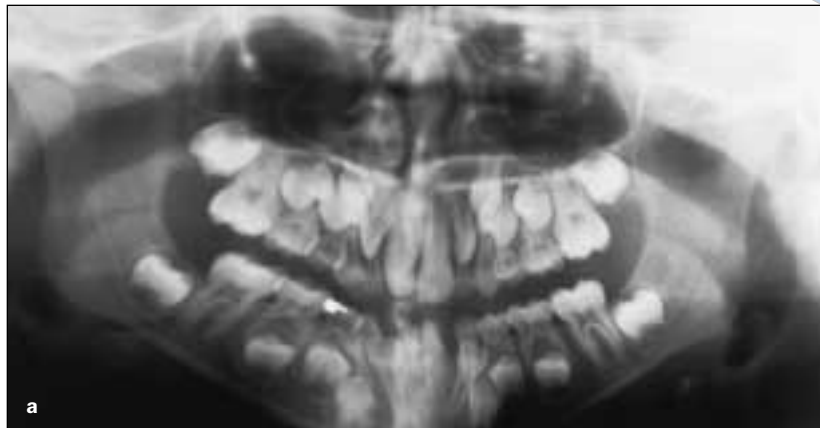
The molars on the right side had erupted against a flush terminal plane of the deciduous second molars; on the left side, the molars tended toward a mesial step or ideal occlusion, which indicated a possible asymmetry (Figs 2d and 2e). There was 3-mm overjet and 5-mm (70%) overbite. Transversely, the maxillary midline was centered to the midpalatal raphe, and the mandibular midline was coincident (Figs 2f to 2h). The maxillary arch was ovoid in form and symmetric. The mandibular arch was also ovoid in form but asymmetric. The mandibular right posterior segment was relatively distal, probably due to mandibular dentoalveolar asymmetry, which explains the tendency for a Class II molar relationship on the right side. The mixed dentition analysis predicted 8 mm of crowding in the mandibular arch and 4 mm of

<sup>1</sup>PhD Candidate, Department of Anatomy and Cell Biology, University of Illinois at Chicago, College of Medicine, Chicago, Illinois, USA.

<sup>2</sup>Professor, Department of Orthodontics, University of Illinois at Chicago, College of Dentistry, Chicago, Illinois, USA.

#### REPRINT REQUESTS/CORRESPONDENCE

Dr Cyril Sadowsky, Department of Orthodontics, University of Illinois at Chicago, College of Dentistry, 801 South Paulina Street, Chicago, IL 60680, USA. E-mail: cyrilsad@uic.edu



**Fig 1** Patient at 9 years 4 months of age. **(a)** Panoramic radiograph. **(b to f)** Initial study casts.

crowding in the maxillary arch. The maxillary and mandibular incisors were rotated and there was a maxillary midline diastema. The curve of Spee was slightly increased and the compensating curve (maxillary arch) was flat.

### **Radiographic evaluation**

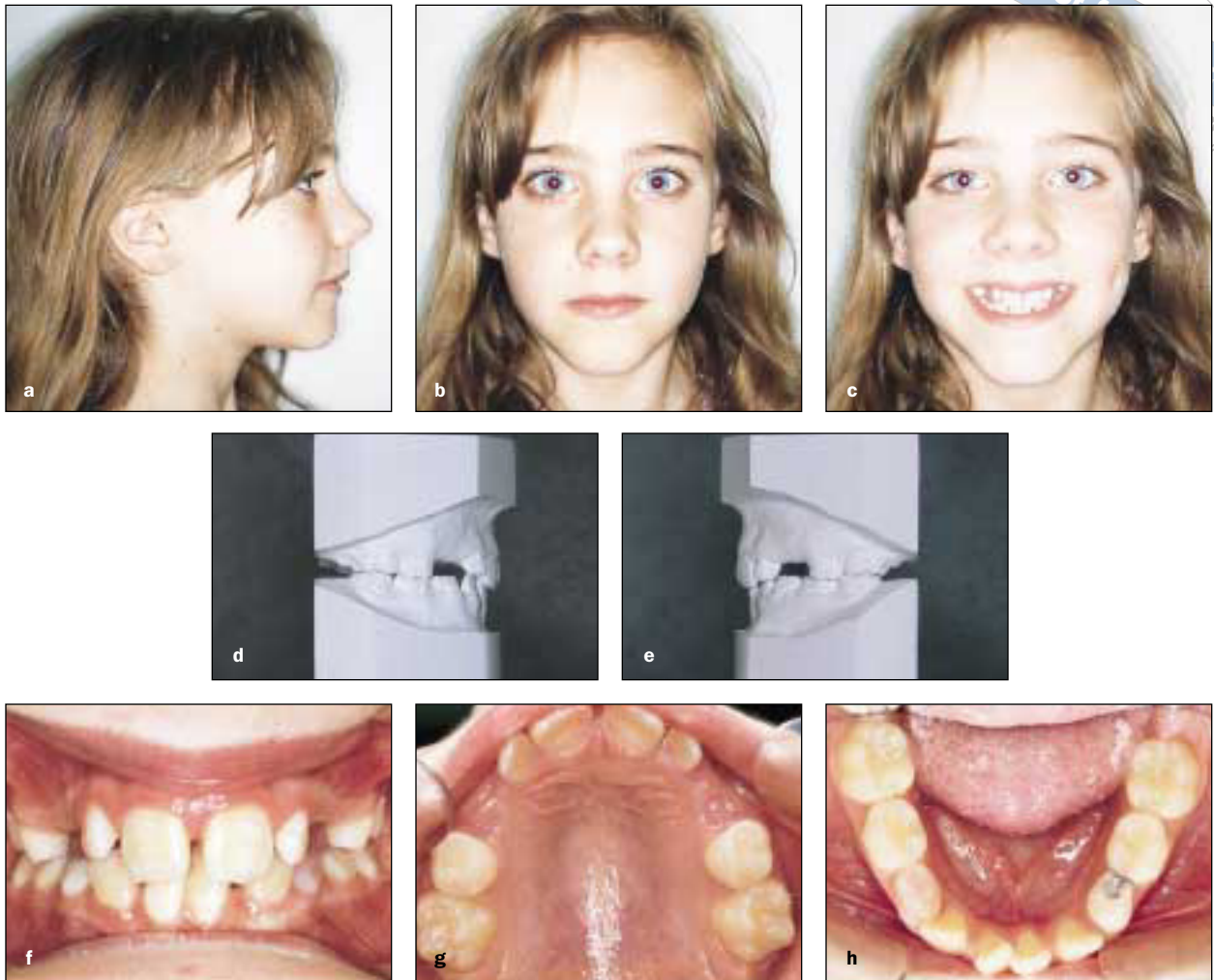
At 12 years 2 months of age, the progress panoramic radiograph indicated that the incisors were fully erupted (Fig 3), as compared to the panoramic radiograph taken 14 months earlier (see Fig 1a). The permanent teeth were developing normally at this time, except for the maxillary third molar tooth buds. The four first premolars appeared to be erupting ahead of the canines. The maxillary canines were developing high and mesially.

### **Cephalometric analysis**

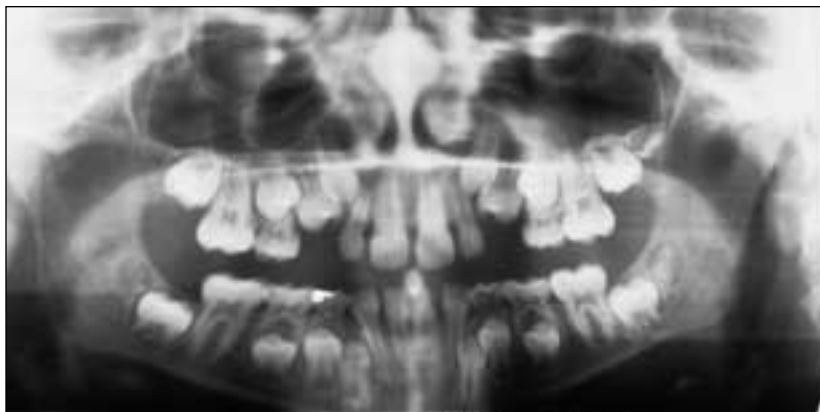
The mandible and the maxilla were well positioned in the face (Fig 4a). Vertically, the mandibular plane angle, Y-axis, and the anterior face height indicated a normal downward and forward growth pattern (Fig 4a, Table 1). The maxillary and mandibular incisors were retroclined and retrusive.

### **Diagnostic summary**

This was essentially a Class I malocclusion with crowding, in the middle mixed dentition stage. The facial and dental pattern was somewhat retrusive. The tendency for a Class II molar relationship on the right side was explained by mandibular crowding of only 3 mm on the right side and 5 mm on the left

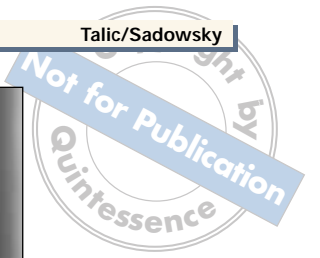


**Fig 2** Patient at 10 years 8 months of age. (a to c) Facial photographs. (d,e) Progress study casts. (f to h) Progress intraoral photographs.



**Fig 3** Progress panoramic radiograph. Patient was 12 years 2 months of age.

**Fig 4** (facing page) Pre-appliance treatment; patient was 14 years 10 months of age. (a) Lateral cephalometric radiograph. (b to f) Intraoral photographs and study casts. (g to i) Facial photographs. (j) Panoramic radiograph.

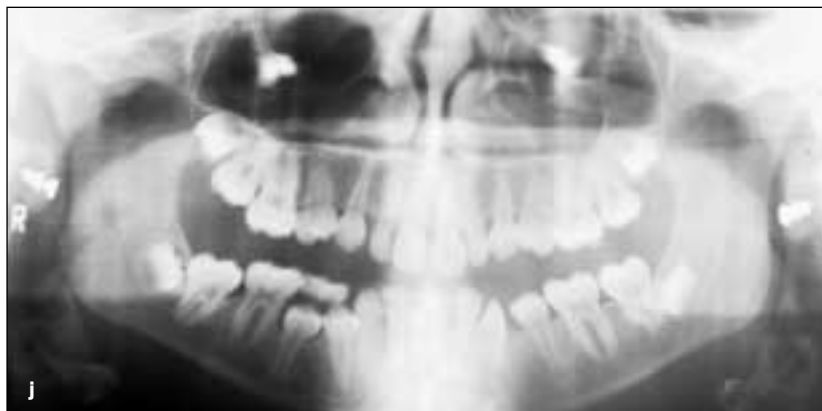
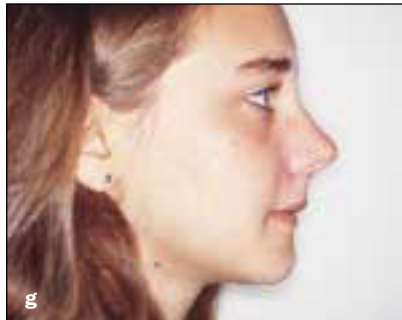
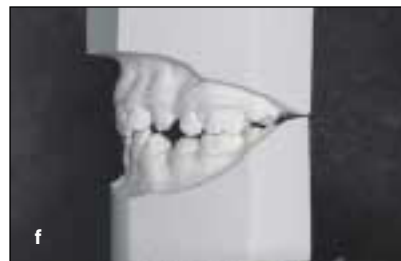
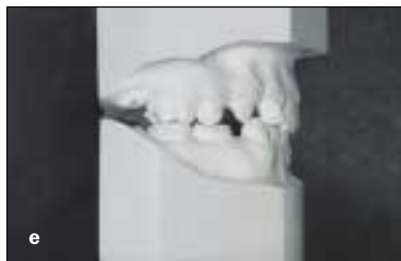
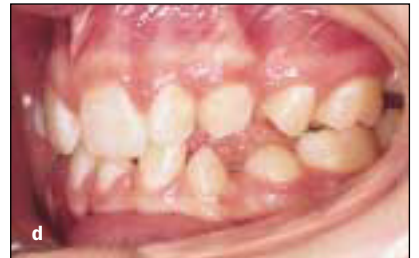
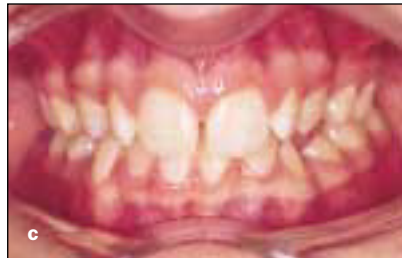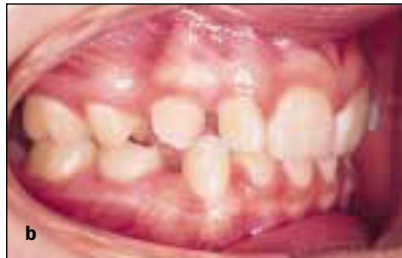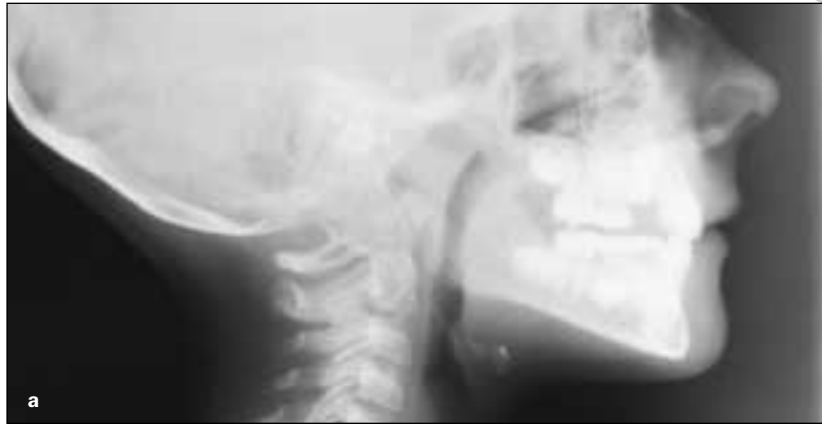Table 1 Cephalometric analyses

	Mean	Initial	Progress	Posttreatment
<b>Skeletal</b>				
SN-FH (deg)	6	10	10	11
Convexity (deg)	6	4	5	-1
A-N.Po (deg)	5	3	2	-1
SNA (deg)	81	79	79	82
A-N vertical (mm)	0	6	3	-3
Facial angle (deg)	86	87	88	89
Po-N vertical (mm)	-2	7	3	-5
Condylion-A (mm)	92	83	87	90
Condylion-GN (mm)	92	83	87	90
Difference (mm)	-22	-19	-24	-25
MP-FH (deg)	25	25	24	22
Y-axis	60	56	56	56
N-Menton (mm)	118	107	111	117
ANS Menton (mm)	66	58	59	63
Wits analysis (mm)	0	3	4	3
ANB (deg)	3	4	4	2
<b>Dental</b>				
Interincisal (deg)	135	147	152	139
L1-MP (deg)	4	1	-2	3
L1-APo line (mm)	2	-2	-2	1
U1-SN (deg)	103	91	92	99
U1-APo (mm)	5	-2	-1	2
<b>Soft tissue</b>				
Facial contour (deg)	-11	-21	-15	-13
UL-E plane (mm)	-2	-3	-7	-7
LL-E plane (mm)	0	-5	-9	-9
Nasolabial angle (deg)	100	138	142	124
Interlabial gap (mm)	1	0	0	0

side. The mandibular right posterior teeth were slightly distal compared to the left side. The etiology was presumed to be genetic. There were no apparent environmental factors.

## PROBLEM LIST

1. Maxillary arch crowding of 4 mm.
2. Mandibular arch crowding of 8 mm.
3. Maxillary canines developing ectopically high and mesially.
4. Tendency for a Class II molar relationship on the right side.
5. Increased overbite.
6. Retrusive dental and facial pattern.

## TREATMENT OBJECTIVES

1. Maintain maxillary and mandibular incisor position anteroposteriorly.
2. Establish normal overbite by extruding posterior teeth and increasing the vertical dimension.

3. Resolve the potential crowding and ectopically developing maxillary canines through a serial extraction protocol, with the possibility of extracting the four first premolars.
4. Ultimately protract the mandibular right posterior segment into normal occlusion.
5. Employ minimal anchorage control to avoid further flattening of the profile.

## TREATMENT PLAN

Following the serial extraction protocol and upon eruption of all the permanent teeth, fixed appliance treatment was planned for tooth alignment, space closure, and establishment of normal symmetric occlusal relationships.

## TREATMENT PROGRESS

The patient, 10 years 9 months of age, was referred to her pediatric dentist for extraction of the mandibular deciduous first molars (see Figs 2d and 2e). The



patient was placed on recall for periodic evaluation. Eruption was slow. Seventeen months later, the maxillary left first premolar was extracted upon eruption. Seven months later, the maxillary right first premolar was extracted (patient was now 13 years of age), followed by extraction of the mandibular left first premolar 3 months later. The mandibular right first premolar was not extracted, since it had not yet erupted.

Progress records were taken at this time (patient was 14 years 10 months of age), prior to placing fixed appliances (Figs 4b to 4j).

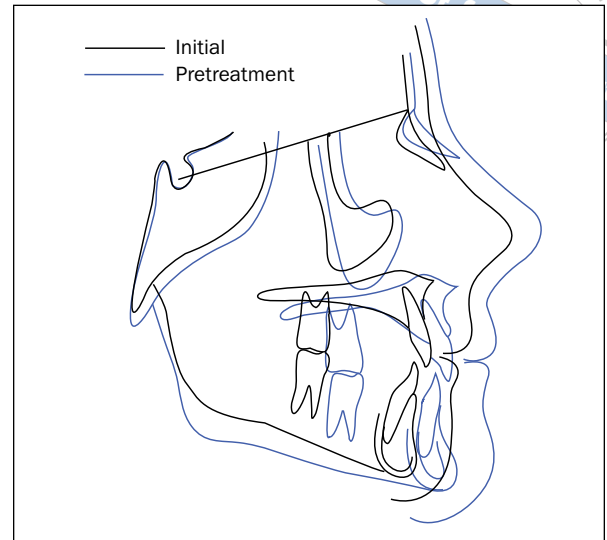
## FIXED APPLIANCE TREATMENT

Edgewise appliances (preadjusted 0.018 × 0.025-inch brackets) were placed on all maxillary teeth by direct bonding, using clear ceramic brackets on the six anterior teeth. A 0.016-inch nickel-titanium (NiTi) archwire was placed for initial alignment. Maxillary canine retraction was initiated, using a 0.016-inch stainless steel round archwire, with an off-center gable bend placed at the mesial surface of the second premolar to aid in maintaining the posterior teeth in an upright position. Canine retraction was completed in the maxillary arch in approximately 4 months. An upper 0.016 × 0.022-inch stainless steel archwire with an increased compensating curve was used to help correct the overbite.

A removable upper bite plate was placed for greater overbite correction; this allowed eruption/extrusion of the posterior teeth and increased the vertical dimension (anterior face height). After 7 months of active treatment, the mandibular right first premolar was beginning to erupt but needed 3 mm of space. The maxillary right canine was in an overcorrected Class I relationship (Class III tendency) and there was spacing between the maxillary right canine and the lateral incisor. The midlines were coincident.

Rather than completing the serial extraction protocol as was originally planned, it was decided *not* to extract the mandibular right first premolar. It was thought that the mandibular anterior teeth could be advanced, the mandibular right posterior teeth uprighted, the maxillary right canine moved mesially, and the maxillary right posterior teeth protracted into a Class II relationship. The original tendency for a Class II molar relationship on the right side became an important consideration.

Fixed appliances were bonded on the mandibular arch, and a 0.016-inch NiTi archwire was used for initial leveling and alignment, progressing to 0.016-inch round and 0.016 × 0.016-inch square stainless steel archwires. At the same time, light Class III elastics were used periodically on the right side for 6 months.



**Fig 5** Cranial base cephalometric superimposition from initial (10 years 8 months) to the pre-appliance treatment stage (14 years 10 months).

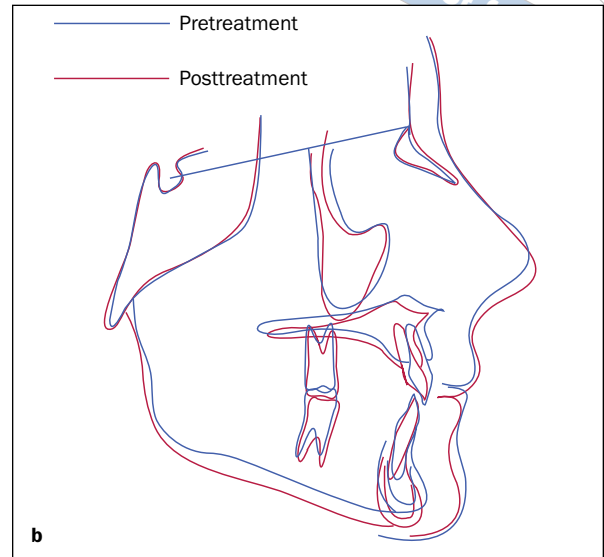
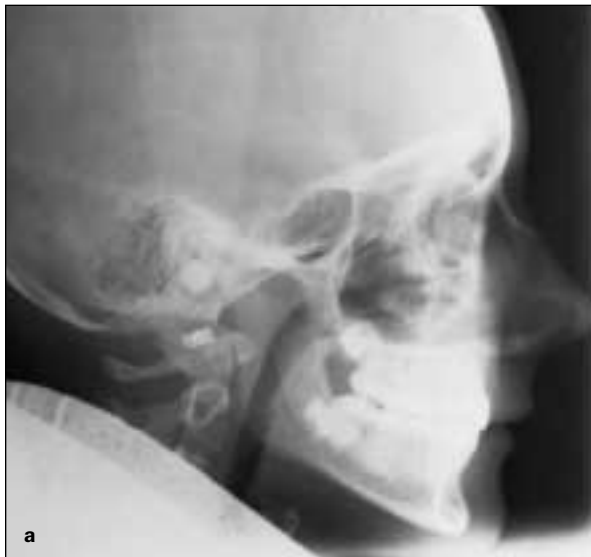Detailing of the occlusion was carried out for 4 months, using 0.016 × 0.022-inch rectangular stainless steel archwires. The total active treatment time was 20 months.

## RETENTION

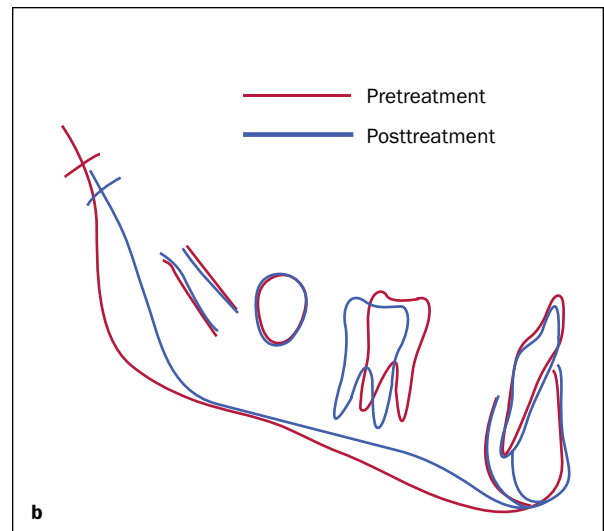
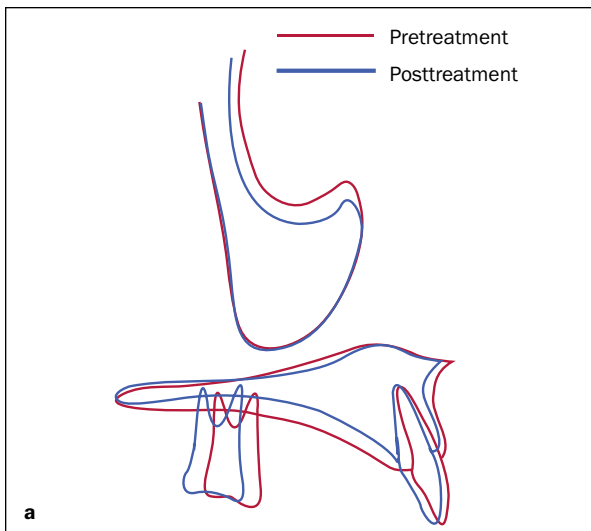
An upper full occlusal Essix (thermoplastic; Raintree Essix, New Orleans, LA, USA) retainer was made and worn only at night. A lower lingual canine-to-canine 0.032-inch blue Elgiloy wire (Rocky Mountain Orthodontics, Denver, CO, USA) was bonded in place to maintain incisor alignment and will remain in place until the patient is approximately 22 years of age.

## RESULTS ACHIEVED

When superimposed on the anterior cranial base and registered on sella, the maxilla and mandible were shown to be displaced in a downward and forward direction, with the mandible exhibiting a closing rotation, as is evident from the initial cephalometric radiograph (10 years 8 months) to the pretreatment radiograph (14 years 10 months) (Fig 5). Significant nasal and soft tissue profile growth also occurred. From the pre-appliance treatment stage (14 years 10 months) to the posttreatment stage (16 years 6 months) some additional nasal growth occurred and the maxilla was displaced downward (Fig 6). The mandible rotated downward and backward, probably as a consequence of treatment.



**Fig 6** (a) Posttreatment lateral cephalometric radiograph. (b) Cranial base superimposition from the pre-appliance treatment stage (14 years 10 months) to the posttreatment stage (16 years 6 months).



**Fig 7** Maxillary and mandibular cephalometric superimpositions from the pre-appliance treatment stage (14 years 10 months) to the posttreatment stage (16 years 6 months).

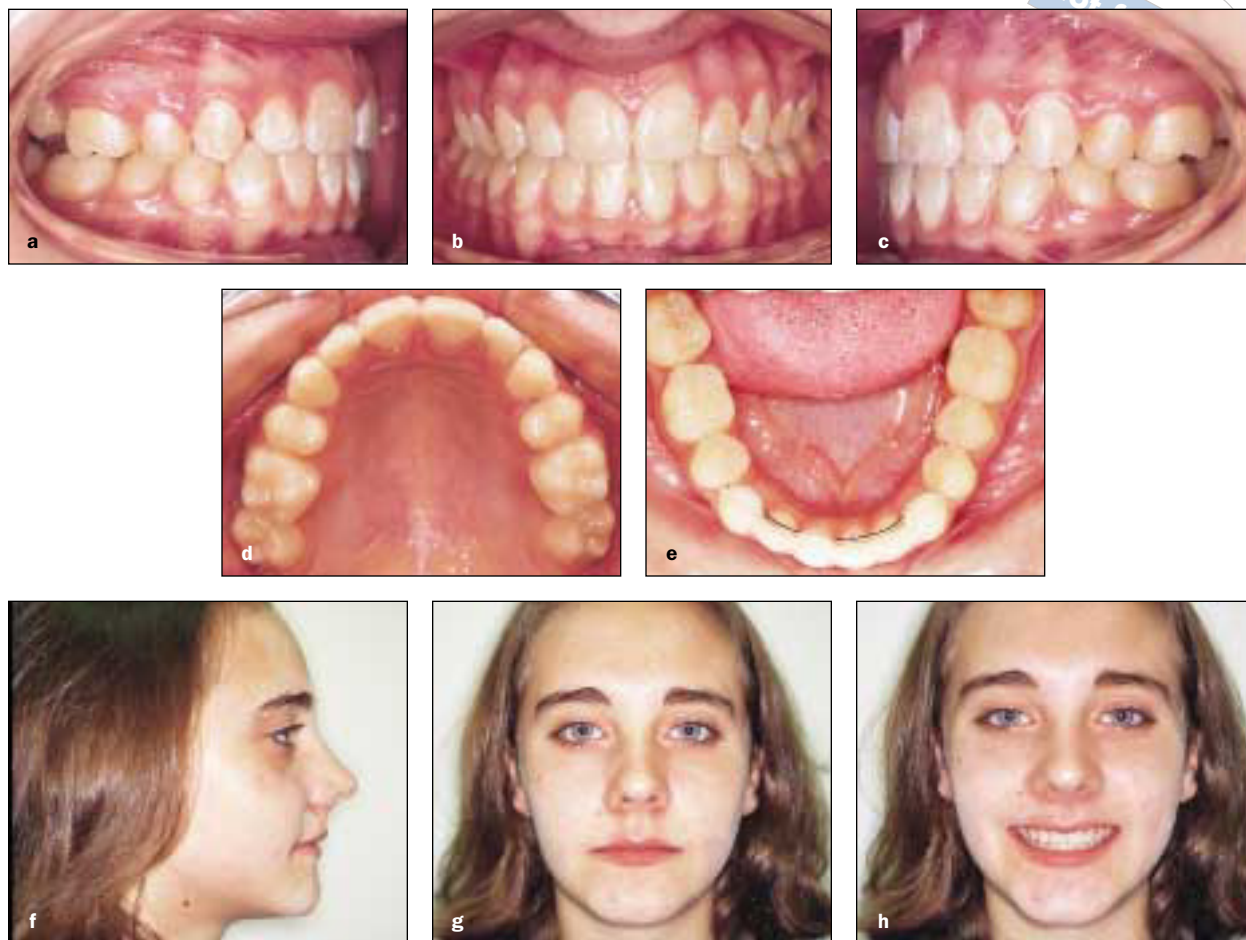
Based upon maxillary superimposition from the pre-appliance treatment cephalometric radiograph (14 years 10 months) to the posttreatment radiograph (16 years 6 months), the maxillary molars moved mesially 3 mm, with minimal vertical movement (Fig 7). The maxillary incisors were slightly proclined, but their relationship to the A-pogonion (APo) line showed minimal change, which helped in avoiding further flattening of the soft tissue profile (see Table 1).

The mandibular superimposition from the pre-appliance treatment stage to the posttreatment

stage showed 3 mm of mesial movement of the mandibular molars and 2 mm of vertical movement.

### **Occlusal relationships**

Occlusal relationships are shown in Figs 8a to 8e. The molars on the right side were finished in a Class II relationship, which was a consequence of the decision not to extract the mandibular right first premolar as was originally planned. The left side and the right canine were finished in a normal Class I relationship.



**Fig 8** Posttreatment (16 years 6 months). (a to e) Intraoral photographs. (f to h) Facial photographs.

Maxillary and mandibular crowding was resolved. The excessive overbite and curve of Spee were corrected by holding the mandibular incisor position vertically as the mandible was rotated downward and backward.

## DISCUSSION

This patient was initially diagnosed as having a Class I malocclusion, with a deep overbite, crowding in the maxillary arch with ectopically erupting canines, and crowding in the mandibular arch. The initial treatment plan included a serial extraction protocol that was to result in the extraction of the four first premolars. However, as treatment progressed, the subtle asymmetry of a Class II tendency on the right side became important. In addition, there was delayed eruption in the mandibular right posterior segment, and the amount of crowding in that segment was relatively minor. It was therefore decided to treat the case to a Class II molar relationship on the right side and not to extract the remaining mandibular right first premolar.

The occlusal outcome achieved on the left side was that of normal overjet, normal overbite, and normal Class I molar and canine relationships. On the right side, the occlusal outcome was that of a normal Class I canine relationship but a Class II molar relationship. The facial profile following treatment remained flat but pleasing (Figs 8f to 8h).

## CONCLUSION

The initial diagnostic challenge was in the decision to extract four premolars in a patient with crowding, an obtuse nasolabial angle, and a straight profile. Some orthodontists might have attempted a nonextraction treatment strategy with different objectives for tooth movements. It was fortuitous that only three premolars were eventually extracted, as this limited the risk of excessive mandibular incisor retraction and further flattening of the profile.

The posttreatment outcome reflects a viable treatment strategy for Class II subdivision malocclusions, in which only three premolars are extracted.